



MLH1-rheMac hereditary nonpolyposis colorectal cancer syndrome in rhesus macaques

David W. Brammer^{a,1}, Patrick J. Gillespie^{b,1}, Mei Tian^{b,1}, Daniel Young^{b,1}, Muthuswamy Raveendran^c, Lawrence E. Williams^d, Mihai Gagea^a, Fernando J. Benavides^e, Carlos J. Perez^f, Russell R. Broaddus^f, Bruce J. Bernacky^d, Kirstin F. Barnhart^d, Mian M. Alauddin^b, Manoop S. Bhutani^g, Richard A. Gibbs^c, Richard L. Sidman^{h,2}, Renata Pasqualini^{i,j}, Wadih Arap^{i,k}, Jeffrey Rogers^c, Christian R. Abée^d, and Juri G. Gelovani^{b,l,m,2}

^aDepartment of Veterinary Medicine and Surgery, The University of Texas MD Anderson Cancer Center, Houston, TX 77030; ^bDepartment of Experimental Diagnostic Imaging, The University of Texas MD Anderson Cancer Center MD Anderson Cancer Center, Houston, TX 77030; ^cHuman Genome Sequencing Center, Department of Molecular and Human Genetics, Baylor College of Medicine, Houston, TX 77030; ^dKeeling Center for Comparative Medicine and Research, The University of Texas MD Anderson Cancer Center MD Anderson Cancer Center, Bastrop, TX 78602; ^eDepartment of Epigenetics and Molecular Carcinogenesis, The University of Texas MD Anderson Cancer Center MD Anderson Cancer Center, Smithville, TX 78957; ^fDepartment of Pathology, The University of Texas MD Anderson Cancer Center MD Anderson Cancer Center, Houston, TX 77030; ^gDepartment of Gastroenterology, Hepatology and Nutrition, The University of Texas MD Anderson Cancer Center MD Anderson Cancer Center, Houston, TX 77030; ^hDepartment of Neurology, Harvard Medical School, Boston, MA 02115; ⁱRutgers Cancer Institute of New Jersey at University Hospital, Newark, NJ 07103; ^jDivision of Cancer Biology, Department of Radiation Oncology, Rutgers New Jersey Medical School, Newark, NJ 07103; ^kDivision of Hematology/Oncology, Department of Medicine, Rutgers New Jersey Medical School, Newark, NJ 07103; ^lKarmanos Cancer Institute, School of Medicine, Wayne State University, Detroit, MI 48201; and ^mDepartment of Biomedical Engineering, College of Engineering and School of Medicine, Wayne State University, Detroit, MI 48201

Contributed by Richard L. Sidman, January 11, 2018 (sent for review December 20, 2017; reviewed by Alberto Bardelli and Paulo Hoff)

Over the past two decades, 33 cases of colonic adenocarcinomas have been diagnosed in rhesus macaques (*Macaca mulatta*) at the nonhuman primate colony of the Keeling Center for Comparative Medicine and Research at The University of Texas MD Anderson Cancer Center. The distinctive feature in these cases, based on PET/computed tomography (CT) imaging, was the presence of two or three tumor lesions in different locations, including proximal to the ileocecal juncture, proximal to the hepatic flexure, and/or in the sigmoid colon. These colon carcinoma lesions selectively accumulated [¹⁸F]fluorodeoxyglucose ([¹⁸F]FDG) and [¹⁸F]fluoroacetate ([¹⁸F]FACE) at high levels, reflecting elevated carbohydrate and fatty acid metabolism in these tumors. In contrast, the accumulation of [¹⁸F]fluorothymidine ([¹⁸F]FLT) was less significant, reflecting slow proliferative activity in these tumors. The diagnoses of colon carcinomas were confirmed by endoscopy. The expression of MLH1, MSH2, and MSH6 proteins and the degree of microsatellite instability (MSI) was assessed in colon carcinomas. The loss of MLH1 protein expression was observed in all tumors and was associated with a deletion mutation in the *MLH1* promoter region and/or multiple single-nucleotide polymorphism (SNP) mutations in the *MLH1* gene. All tumors exhibited various degrees of MSI. The pedigree analysis of this rhesus macaque population revealed several clusters of affected animals related to each other over several generations, suggesting an autosomal dominant transmission of susceptibility for colon cancer. The newly discovered hereditary nonpolyposis colorectal cancer syndrome in rhesus macaques, termed *MLH1*-rheMac, may serve as a model for development of novel approaches to diagnosis and therapy of Lynch syndrome in humans.

adrenal glands in up to 34% of cases (12). However, the etiology of colon carcinomas in rhesus macaques remains unclear. Potential carcinogens in the diet have been suggested as a contributing factor (11), which is unlikely because of a controlled diet, a relatively low-stress environment, lack of exposure to known carcinogens, and good veterinary care of macaques housed in academic research centers. Infectious causes and various genetic mutations causing spontaneous colon carcinomas in rhesus macaques have also been suggested (12). Here, we reveal the existence of hereditary nonpolyposis colon cancer syndrome in a rhesus macaque population, which is associated with multiple single-nucleotide polymorphism (SNP) mutations in the *MLH1* gene and a deletion mutation in its promoter region.

Significance

The discovery of *MLH1*-rheMac hereditary nonpolyposis colorectal cancer syndrome in rhesus macaques (*MLH1*-rheMac HNPCC), which is an orthologue of Lynch syndrome in humans, is highly significant in the field of oncology. The hereditary nature of this disease should allow for planned cross-breeding of rhesus macaques to assess the effects of homozygous versus heterozygous *MLH1* gene mutations, as well as other comutations and environmental factors that may affect the development of colon cancers. Also, the *MLH1*-rheMac HNPCC syndrome in rhesus macaques can serve as an important model for development of novel approaches to diagnosis and therapy of Lynch syndrome in human patients.

rhesus macaque | colon carcinoma | hereditary | *MLH1* | single-nucleotide polymorphism

Author contributions: D.W.B., P.J.G., F.J.B., R.R.B., B.J.B., M.S.B., R.P., W.A., J.R., C.R.A., and J.G.G. designed research; D.W.B., P.J.G., M.T., D.Y., M.R., L.E.W., M.G., F.J.B., C.J.P., R.R.B., K.F.B., M.M.A., M.S.B., R.A.G., J.R., and J.G.G. performed research; F.J.B., M.M.A., and M.S.B. contributed new reagents/analytic tools; D.W.B., M.T., D.Y., F.J.B., M.S.B., J.R., and J.G.G. analyzed data; and D.W.B., P.J.G., M.T., F.J.B., J.R., R.L.S., R.P., W.A., C.R.A., and J.G.G. wrote the paper.

Reviewers: A.B., Institute for Cancer Research and Treatment and University of Torino; and P.H., Faculdade de Medicina da Universidade de São Paulo and Institute of Cancer of São Paulo.

The authors declare no conflict of interest.

This open access article is distributed under [Creative Commons Attribution-NonCommercial-NoDerivatives License 4.0 \(CC BY-NC-ND\)](https://creativecommons.org/licenses/by-nc-nd/4.0/).

¹D.W.B., P.J.G., M.T., and D.Y. contributed equally to this work.

²To whom correspondence may be addressed. Email: richard_sidman@hms.harvard.edu or juri.gelovani@wayne.edu.

This article contains supporting information online at www.pnas.org/lookup/suppl/doi:10.1073/pnas.1722106115/-DCSupplemental.

Published online February 28, 2018.

Gastrointestinal cancers are the most common types of cancers in aged nonhuman primates (1, 2) and account for 13% of all tumors in macaques (3). In rhesus macaques (*Macaca mulatta*), the incidence of intestinal adenocarcinomas increases with age from 3.2% for animals aged 13–19 y to 20.7% for animals aged over 30 y (4). A recent study on the incidence of spontaneous neoplasia in 2,660 captive rhesus macaques identified 217 with neoplastic diseases, among which gastrointestinal system neoplasms were diagnosed in 48.8% of cases (5). The colon and ileocecal junction are the most common locations for carcinomas in macaques, with the cecum representing the majority of cases (1–12). Metastases are frequently observed in the local and peripheral lymph nodes, liver, lungs, pancreas, and

Results and Discussion

Over the past two decades, 33 cases of colonic adenocarcinomas have been diagnosed in rhesus macaques (*M. mulatta*) at the nonhuman primate colony of the Keeling Center for Comparative Medicine and Research at The University of Texas MD Anderson Cancer Center. This rhesus macaque colony was founded in 1974 from 360 rhesus monkeys of Indian origin, of which 133 were wild-caught and the other 227 were derived from 10 domestic breeding colonies. An additional 31 females were introduced in 1980, and four males were introduced in 1985. The colony was closed to further immigration in 1985 (13).

In 1997, the first case of a stenosing colon adenocarcinoma in a female rhesus monkey from this colony was reported (10). More recently, additional colon carcinoma cases in rhesus macaques have been identified during routine PET/computed tomography (CT) imaging studies for the assessment of pharmacokinetics, biodistribution, metabolism, and radiation dosimetry of novel imaging agents (14, 15). These colon carcinoma lesions selectively accumulated [¹⁸F]fluorodeoxyglucose ([¹⁸F]FDG) and [¹⁸F]fluoroacetate ([¹⁸F]FACE) at high levels (Fig. 1 A–D and *SI Appendix, Figs. S1 and S2*), reflecting elevated carbohydrate and fatty acid metabolism in these tumors. Furthermore, [¹⁸F]FDG accumulation was observed not only in tumors but also in the peritumoral tissues, suggesting an inflammatory process. In contrast, the accumulation of [¹⁸F]fluorothymidine ([¹⁸F]FLT) was low (Fig. 1 E and F), reflecting slow proliferative activity in these tumors. A distinctive feature in these cases was the presence of two or three tumor lesions in different locations, including proximal to the ileocecal juncture, proximal to the hepatic flexure, and/or in the sigmoid colon. The diagnoses of colon carcinomas were confirmed by endoscopic examination (Fig. 1G). These tumors typically formed an annular or “napkin-ring” constriction of the colon (SI Appendix, Fig. S1E), often with an ulcerated central region and dilation of the colon proximal to the tumor (SI Appendix, Fig. S1G). Histopathological examination of resected tumors revealed colonic adenocarcinomas with desmoplastic and infiltrative features that penetrated the muscularis mucosae and invaded the inner and outer muscular layers of the large intestinal wall (SI Appendix, Fig. S3 A and B). In advanced cases, tumor invasion into the mesentery (SI Appendix, Fig. S3 C–E) and mesenteric lymph nodes (SI Appendix, Fig. S3 F and G) was observed.

The multifocal nature of these colon carcinomas and histopathological features also resembled those observed in human patients with Lynch syndrome (16, 17). Lynch syndrome is one of the most common hereditary colorectal carcinoma syndromes in humans, accounting for 1–4% of all colorectal cancers and about

10% of cases before the age of 50 y (18–20). In humans, Lynch syndrome, or hereditary nonpolyposis colorectal cancer syndrome (HNPCC), is diagnosed with the Amsterdam criteria, which include the following: histologically confirmed colon carcinomas must be observed in at least three relatives, including one first-degree relative and one with diagnosis before the age of 50 y; two successive generations must be involved, and familial adenomatous polyposis should be excluded (21–23). The Bethesda guidelines for diagnosis of Lynch syndrome include an additional assessment of microsatellite stability (24).

Germline mutations of four genes involved in DNA mismatch repair (MMR) are associated with Lynch syndrome: *MLH1*, *MSH2*, *MSH6*, and *PMS2*, with over 90% of cases attributed to mutations in the *MLH1* and *MSH2* genes (25–31). The loss of DNA MMR, increased microsatellite instability (MSI), and loss of heterozygosity are contributing factors in the etiology of tumors associated with HNPCC (32, 33). Analyses of MSI, along with characterization of MMR gene mutations and immunohistochemical analyses of their expression in tumors, are currently used for the diagnosis of Lynch syndrome.

Therefore, we assessed the expression of *MLH1*, *MSH2*, and *MSH6* proteins and the degree of MSI in colon carcinomas resected from the three recently diagnosed rhesus macaques. We observed loss of *MLH1* protein expression in tumor cells and a significant decrease in *MLH1* expression levels in tumor stromal cells (Fig. 2). Also, a significant decrease of *MLH1* expression was observed in 41% (11 of 27 of cases) of the affected animals, and the loss of *MLH1* expression was observed in stromal tumor cells and normal colon mucosa in 30% of the affected animals (eight of 27 cases) (SI Appendix, Fig. S4). A retrospective analysis of colon carcinomas from our pathology archive (paraffin-embedded specimens) gave similar results; none of the tumors expressed *MLH1* protein in the tumor cells, and a significant decrease or loss of *MLH1* expression was observed in the stroma and in normal colon mucosal epithelial cells in some cases. The results of immunohistochemical analyses of *MLH1*, *MSH2*, and *MSH6* expression in colon carcinomas and normal colon in the rhesus macaques included in this study is summarized in SI Appendix, Table S1.

MSI is observed in about 15% of sporadic colorectal cancers (34) and most HNPCC (18–20, 35). Multiple errors in repetitive DNA sequences (microsatellites) result from a failure of the DNA MMR system to edit errors made during DNA replication. Based on eight microsatellite markers (six rhesus-specific dinucleotides and two human mononucleotides) all tumors exhibited an MSI phenotype. For samples J72 and J106, we found clear instability for BAT-26 (SI Appendix, Fig. S5). Tumors from J72 and J106 could be classified as microsatellite-unstable

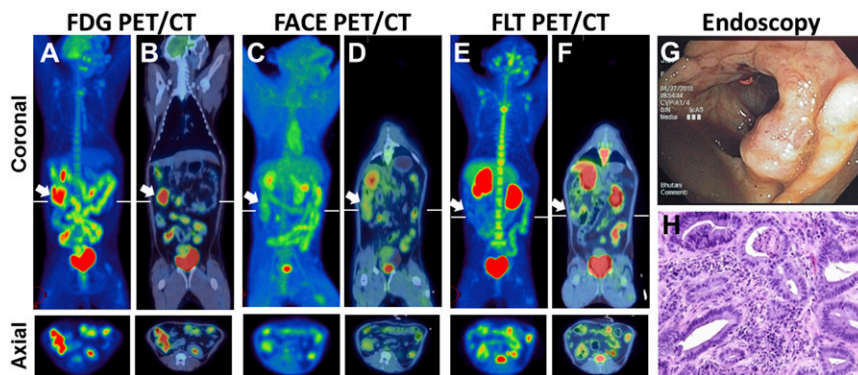


Fig. 1. Twenty-year-old female rhesus monkey (J123) with colonic adenocarcinoma. [¹⁸F]FDG (A and B), [¹⁸F]FACE (C and D), and [¹⁸F]FLT (E and F) images were obtained with PET (A, C, and E) and PET/CT (B, D, and F), demonstrating multifocal colon carcinoma (white arrows). White bars indicate the axial image plane. (G) Endoscopic image of colon carcinoma (field: 5-cm diameter). (H) H&E-stained histological section shows an invasive cecal adenocarcinoma. (Magnification: 200×.)

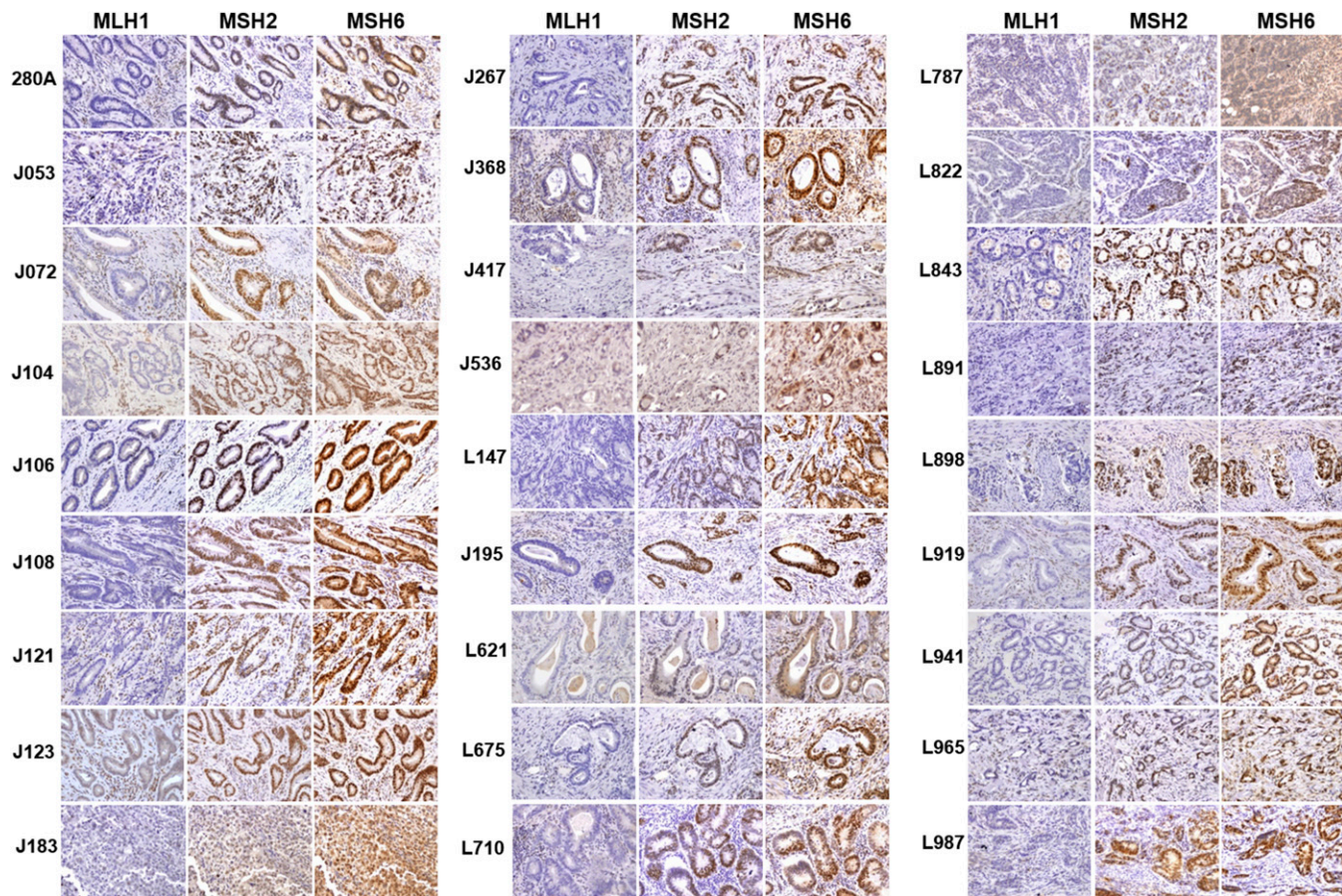


Fig. 2. Immunohistochemical staining for MLH1, MSH2, and MSH6 of tumor tissues obtained from the affected rhesus macaques. Individual animal identifiers are on the left side of each horizontal trio of histological images. (Magnification: 20 \times .)

colorectal cancers. Analysis of 16 other confirmed adenocarcinoma cases revealed that some tumors exhibit MSI (MSI-H) and others exhibit low MSI (MSI-L), whereas some are stable (MSI-S), as defined by Kurzawski et al. (36). A summary of MSI markers in 12 selected tumors is shown in *SI Appendix, Table S2*.

The pedigree analysis of this rhesus macaque population revealed several clusters of affected animals related to each

other over several generations, which suggested autosomal dominant transmission of susceptibility for the development of colon cancer (Fig. 3 and *SI Appendix, Figs. S6–S9*). All colon carcinoma cases in this colony could be traced back to three founding male rhesus monkeys. In particular, the largest cluster of rhesus macaques with MLH1-negative colon carcinomas (10 confirmed cases) could be traced back to one male (821i)

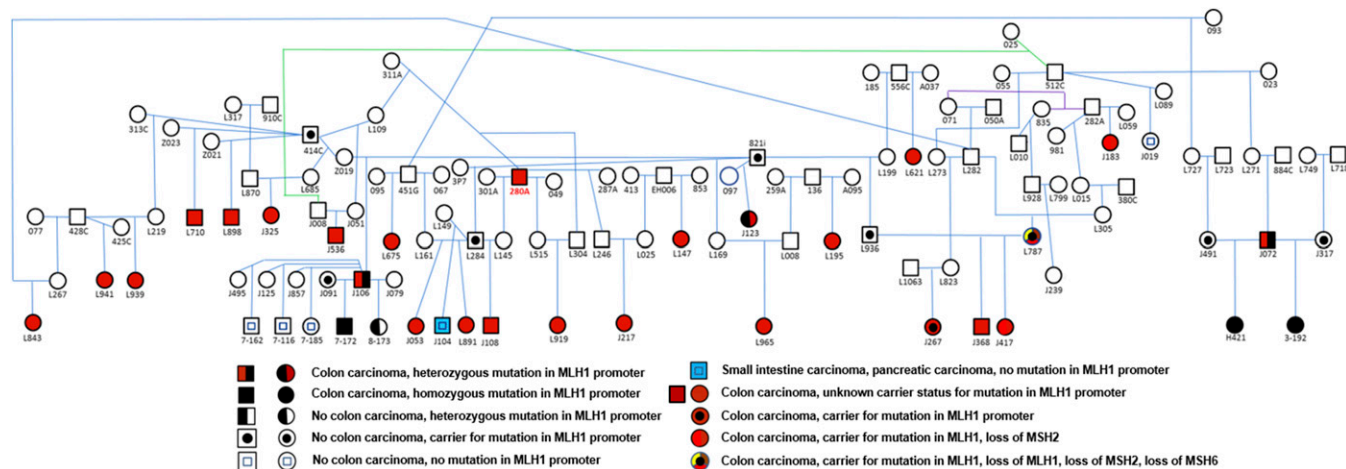


Fig. 3. Pedigree analysis of this rhesus macaque population. Several clusters of affected animals are related to each other over several generations, which suggests an autosomal dominant transmission of susceptibility for the development of colon cancer.

(Fig. 3 and *SI Appendix*, Fig. S6 and S7). This founding member of the colony fathered 57 first-generation offspring from 1977 until 1993. Two of the offspring with colon cancer (J123 and J106) share the same SNP pattern and *MLH1* promoter deletion described above. The other eight macaques with cancer were born into subsequent generations. Noteworthy, one animal (J104) that developed small intestinal adenocarcinoma and pancreatic carcinoma had a normal *MLH1* promoter sequence and only one SNP in common with J123, J106, and J072. Also, it should be noted that not all of the offspring of 821i were kept in the breeding colony, and the incidence of cancer in the other 47 animals is not known. According to the pedigree, animal J072, which shares the same SNP pattern as J123 and J106 and the promoter deletion, is part of another family (Fig. 3 and *SI Appendix*, Fig. S8). Other interesting observations in the 282A lineage are as follows: J183 had loss of *MLH1* and loss in *MSH2* in the majority of tumor cells; L787 had loss of *MLH1* and a marked decrease or loss in *MSH2* in the majority of tumor cells, as well as loss of *MSH6* expression; J417 had loss of *MLH1* and a marked decrease or loss in *MSH2* in tumor cells; and J368 had loss of *MLH1* (Fig. 3 and *SI Appendix*, Fig. S9). Thus, there is a clear pattern of dominant transmission of susceptibility to cancer in several kindreds in this population of rhesus macaques. The age at diagnosis of colon carcinomas in these rhesus macaques was 17.9 ± 3.5 y, which is somewhat earlier than the typical age (>20 y) reported for high incidence of spontaneous colorectal carcinomas (4, 6, 7, 11, 12).

To identify the hereditary transmitted mutations causing the loss of *MLH1* protein expression or function, we sequenced the entire *MLH1* gene from tumor and blood-derived DNA in three initially diagnosed animals and in their 14 progeny animals. Sequencing included the 1,600-bp fragment upstream of adenine–thymine–guanine (ATG) trinucleotide sequences, covering the putative promoter region, and all 19 exons and introns (a total of 88.6 Kbp) of the *MLH1* gene sequence described in the rhesus macaque genome (37). One non-tumor-bearing, nonrelated animal served as a control. All DNA sequences were compared with the rhesus monkey reference genome samples of NC_007859 (47,230 bp and 15 exons on rhesus chromosome 2 from 99,514,335–99,561,565) and NW_001112905.1 (3,707 bp with four exons from unlocalized chromosome 2 genomic scaffolds). Although the NW_001112905 has not been previously mapped to rhesus chromosome 2, our analysis demonstrated that it is homologous to the human sequence spanning exons 15–19.

A total of 124 SNPs were identified, in which three were exonic SNPs (in exons 12, 13, and 14) and the remaining SNPs were within introns. The heterozygous exon 14 SNP (rheMac2: 2:99,516,382; hg19: 3:37,081,750; c.1632 G > A) is a synonymous SNP present in only one nonaffected monkey, which served as a normal control. The other two heterozygous exonic SNPs were nonsynonymous (*SI Appendix*, Table S3). The SNP in exon 13 results in an amino acid change from arginine to glutamine (rheMac2: 2:99,528,228; hg19: 3:37,070,325; c.1460 G > A), and the SNP in exon 12 results in an amino acid change from threonine to proline (rheMac2: 2:99,531,241; hg19: 3:37,067,311; c.1222 A > C). Previously, a mutation in the same c.1222 (c.1222_1223insT) has been described to cause Lynch syndrome in humans (38). The SNP in exon 13 has been reported twice in patients with colon cancer in the Leiden Open Variation Database (www.lovd.nl/2.0/index.php; nos. 1008137 and 0041020) resulting in an amino acid substitution identical to that observed in the rhesus macaque.

Furthermore, a heterozygous deletion in the putative promoter region of the *MLH1* gene (rheMac2: 2:99,561,829–99,561,830; hg19: ~3:37,034,780; c.–258_259) was identified in three parent monkeys and their progeny, but not in the normal control monkey (*SI Appendix*, Table S4). It should be noted that the human *MLH1* promoter sequence (NM_000249.2), 5' GA(TC)⁴TAA 3', differs from the monkey *MLH1* promoter

sequence [NC_007859 and L627 colon *MLH1*(+)], 5' GA(TC)⁴TAA 3'. The deletion mutant *Mlh1* promoter exhibited 76% weaker transcriptional activity in comparison with the wild-type promoter, as demonstrated by luciferase reporter assay (Fig. 4). This heterozygous dinucleotide deletion is within the same region of the *MLH1* gene promoter which causes the loss of *MLH1* gene expression in humans upon hypermethylation (39, 40). This *MLH1* promoter region includes the DNA binding sequence of the CDP-CR transcription factor, which interacts with CCAAT boxes to facilitate transcription (41). Similarly, a single-nucleotide substitution (–107C → G) in the *MLH1* promoter found in colorectal cancer populations has been shown to reduce transcriptional activity (42). The mutation –42C > T in the promoter region of the *MLH1* gene, localized within a putative Myb protooncogene binding site, has been described in a Newfoundland kindred, meeting the Amsterdam Criteria for Lynch syndrome (or HNPCC) (43). The –93G > A mutation in the *MLH1* gene promoter also increases the risk of microsatellite-unstable colorectal cancers (44). Hypermethylation of this *MLH1* promoter region, including the region corresponding to the nucleotide pair deleted in monkeys, has been reported to cause Lynch syndrome in humans (45). Functional inactivation of the *MLH1* promoter by hypermethylation was shown to cause an MSI phenotype (46, 47) and to be associated with Lynch syndrome (48). It has been suggested that when the functional allele of *MLH1* is lost as part of the loss of the heterozygosity process, only the mutated copy remains, thereby significantly decreasing the amount of functional *MLH1* protein produced (45). Also, it has been recently demonstrated that targeted genetic inactivation or temozolomide-induced loss of *MLH1* expression in colorectal cancer, breast carcinoma, and pancreatic carcinoma leads to persistent accumulation of secondary mutations and widening of the tumor antigen spectrum, whereas the *MLH1*-proficient cancer cells exhibit a stable mutational load and tumor antigen spectrum over time (49). Therefore, we hypothesized that germline

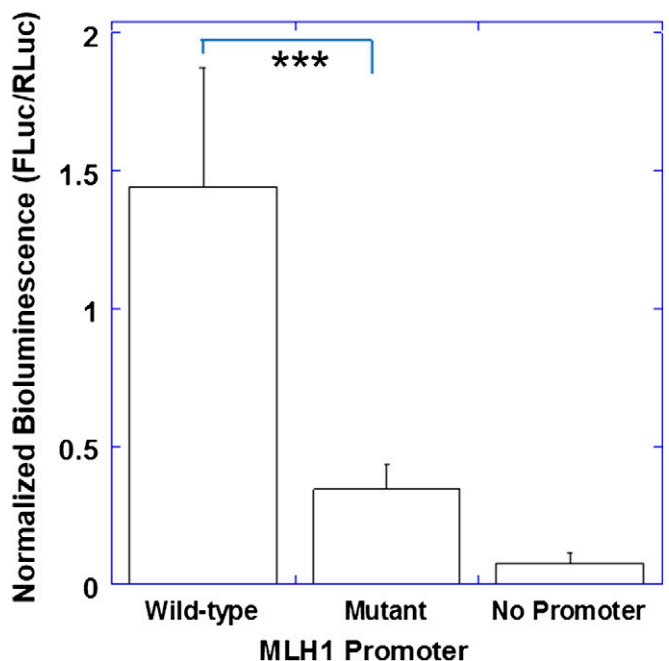


Fig. 4. Deletion mutant *MLH1* promoter exhibits 76% weaker transcriptional activity in comparison to the wild-type promoter, as demonstrated by a dual-luciferase reporter assay. The promoter-inducible Firefly luciferase (Fluc) bioluminescence intensity has been normalized by constitutively expressed Renilla luciferase (Rluc) bioluminescence intensity. *** $P < 0.001$.

transmission of the deletion mutation in the *MLH1* promoter identified in this study may contribute, at least in part, to the low level of *MLH1* expression, which may lead to the development of colon carcinomas in animals bearing this mutation.

Using DNA sequence analysis of the *MLH1* promoter, we demonstrated the presence of mutations in multiple generations within the same family (e.g., from the 821i lineage: J106 heterozygous, 7-172 homozygous, and 8-173 heterozygous; from the 512C lineage: J72 heterozygous, H421 homozygous, and 3-192 also homozygous). Interestingly, two independent female macaques (J491 and J317) are both carriers of the same mutation. DNA analysis demonstrated that the male, J72, who is heterozygous for the promoter mutation, generated progeny that were homozygous for this mutation when mated with each of the females indicated above. This observation strengthens the suggestion that the observed *MLH1* mutation is a true germline mutation causing the hereditary colorectal cancer syndrome in rhesus macaques. Additional studies are required to determine the relative frequency of these *MLH1* mutations by DNA sequence analysis of blood samples obtained from other populations of rhesus macaques.

Herewith, we propose a new terminology for distinguishing this syndrome in rhesus monkeys from the Lynch syndrome known in humans. The new term defining this HNPCC syndrome in rhesus macaques should consist of the name of the gene that is mutated followed by “-rheMac,” which is the same acronym that is used for the rhesus monkey genome assembly. For example, the current 33 cases of colon cancer that do not express *MLH1* would be defined as the *MLH1*-rheMac syndrome. The nomenclature system can be expanded in the future: As rhesus monkeys are identified with *MSH2*, *MSH6*, and *PMS2*, their syndrome can be identified as *MSH2*-rheMac, *MSH6*-rheMac, and *PMS2*-rheMac.

Screening methods described in this study provide an opportunity for a number of additional studies related to *MLH1* and colon cancer. Further analyses can address other known characteristics of *MLH1* defects, such as endometriosis, and cancers of the endometrium, ovary, urinary tract, stomach, small bowel, biliary tract, and brain. The identification of breeding-age rhesus monkeys with *MLH1*, *MSH2*, and *MSH6* deficiencies could lead to the establishment of a breeding colony with defined DNA MMR gene deficiencies.

In summary, current results provide supportive evidence for the existence of HNPCC (*MLH1*-rheMac syndrome) in rhesus macaques resulting from the loss of *MLH1* protein expression, which represents a simian ortholog of Lynch syndrome in humans. The loss of *MLH1* expression is potentially due to several reasons, including a deletion mutation in the *MLH1* promoter region, which results in decreased transcriptional activity. Also, several SNPs in the *MLH1* gene were associated with *MLH1*-rheMac syndrome in rhesus macaques. Although similar SNPs have been shown to cause Lynch syndrome in humans, we cannot definitively state at this time that these SNPs cause the *MLH1*-rheMac syndrome in rhesus macaques. Additional studies of functional consequences of these SNPs in the *MLH1* gene are pertinent, as well as systematic genetic screening of different colonies of rhesus macaques to identify animals carrying the observed mutations in the *MLH1* gene, which may have developed or may develop colon carcinomas. Furthermore, rhesus macaques with *MLH1*-rheMac syndrome may provide an important resource for studies of the pathogenesis of the colon carcinomas under controlled conditions, including studies of environmental and other factors that may interact with genetic risk factors that may influence the onset and progression of colon carcinomas and other cancers associated with Lynch syndrome, as well as for evaluation of novel drugs and diagnostic agents that may improve the outcome of treatment of Lynch syndrome in human patients.

Methods

PET/CT Imaging. The animals were premedicated with 0.04 mg/kg i.m. atropine sulfate and sedated with 10–15 mg/kg i.m. ketamine, followed by intubation and inhalation anesthesia with 1–3% isoflurane in oxygen via Excel 210 SE (Ohmeda). PET/CT imaging studies were performed with Discovery STE16 (GE Healthcare) at 1 h after i.v. administration of [¹⁸F]FDG (8 mCi) or [¹⁸F]FACE (8 mCi), or 3'-[¹⁸F]FLT (8 mCi). PET/CT imaging studies with each radiotracer were performed on different days, all within a period of 3 wk. The details of PET/CT image acquisition and processing are provided elsewhere (14, 15).

Endoscopy. Bowel preparation began 2 d before inoculation. On the first day, the feed was restricted to one portion of food in the morning, mixed with five tablets of sodium phosphate (Visicol) to help empty the rectum. Next day, a polyethylene glycol 3350 solution (30 mL/kg; NuLYTELY) with electrolyte solution was employed as a bowel-cleansing agent, and the animals were fasted overnight. The animals were premedicated with 0.04 mg/kg i.m. atropine sulfate and sedated with 10–15 mg/kg i.m. ketamine, followed by intubation and inhalation anesthesia with 1–3% isoflurane in oxygen via Excel 210 SE. Endoscopic examination was performed with the animal in the left lateral position using a standard endoscope (GIF-H180; Olympus America, Inc.).

Immunohistochemistry. Immunohistochemistry was performed in paraffin-embedded tumor tissue sections and normal colon samples from newly diagnosed animals (necropsy material). Five-micrometer sections of tumor tissue were mounted on Superfrost/Plus microscope slides (catalog no. 12-550-15; Fisher). Antigen retrieval was performed by microwave heating in sodium citrate buffer (pH 6.0) for 10 min. Slides were then incubated in 3% H₂O₂ for 15 min and blocked with 2% normal horse serum (ABC kit, PK-6102; Vector Laboratories) for 1 h. The slides were incubated with mouse monoclonal antibodies to *MLH1* (1:100) (51-1327GR; BD Pharmingen), to *MSH2* (1:100) (NA27; Calbiochem), and to *MSH6* (1:200) (610918; BD Transduction laboratories) at 4 °C overnight. Biotinylated anti-mouse IgG was used as a secondary antibody at a 1:200 dilution (BA-2000; Vector) for 30 min. The chromogen was 3,3'-diaminobenzidine, and counterstaining was performed with hematoxylin. Photomicrographs of stained tissue sections were obtained with a BX51 microscope (Olympus).

MSI. In total, 12 formalin-fixed, paraffin-embedded (FFPE) tumor samples (representing 12 monkeys) were analyzed for MSI. Of these, eight were obtained by manual dissection and four were obtained by laser capture microdissection (LCM). Normal tissue (i.e., liver, kidney) was also collected from FFPE blocks from seven monkeys. These seven normal/tumor pairs were analyzed for MSI with human mononucleotides and rhesus dinucleotides. The other five tumor samples were analyzed with only human mononucleotides. LCM was performed with a PixCell II system (Arcturus Engineering, Inc.) as described elsewhere (50). Briefly, slides were stained with hematoxylin and eosin, examined under a light microscope, and microdissected. Samples were purified with a fixed-tissue genomic DNA purification kit (Promega).

For the MSI screening, we used eight markers, adapted from the National Cancer Institute recommendations (24, 33). Human intragenic microsatellites BAT-25 and BAT-26 were selected as the only mononucleotide markers with which to study microsatellite status in tumors from rhesus macaques. We redesigned and tested new primers based on comparative DNA sequence analysis of rhesus and human *KIT* (BAT-25) and *MSH2* (BAT-26) genes. Being quasimonomorphic in the human population, these markers circumvent the need for normal tissue (24). Since our attempts to amplify rhesus DNA with human dinucleotide markers from the Bethesda panel failed, we selected a set of six dinucleotides microsatellites previously described for rhesus macaques (51): MML357, MML451, MML1151, MML1653, MML1752, and MML1853. Markers were PCR-amplified with fluorescently labeled primers (6FAM, VIC, or NED; Applied Biosystems) as described elsewhere (52). The PCR amplifications were performed with Eppendorf MasterCycler Gradient (Eppendorf). Samples were loaded in a 96-well plate, denatured at 95 °C for 5 min, and analyzed by capillary electrophoresis in an ABI Prism 3130XL instrument (Applied Biosystems) with POP4 polymer (Applied Biosystems). The alleles were visualized and scored with GenMapper software v.4.0 (Applied Biosystems). The degree of instability in the tumor samples was scored according to the percentage of the eight markers showing allele shifts as stable (MSI-S, no markers showing instability), low (MSI-L, one to two markers showing instability), or high (MSI-H, more than three markers showing instability). All samples showing allele shifts were studied twice.

DNA Sequencing. We resequenced the *MLH1* gene (including ~1,600 bp 5' to exon 1) in affected and unaffected macaques. The DNA samples included the L627 control, which expresses *MLH1* in the colon, as well as J123, J106, and J72 (MLH1-negative) and 12 offspring of J106 and J72. DNA was extracted from white blood cells or liver samples by standard phenol/chloroform methods. The human *MLH1* has 19 exons and the rhesus reference (rhmac2) has exons 1–15. The remaining four exons are in rhesus unlocalized scaffold NW_001112905.1, which is not mapped to rhmac2. We used both reference and unmapped rhesus scaffold sequences to design primers to amplify the full segments (exons 1–19, promoter, UTRs, and introns) of the rhesus *MLH1* gene. The full set of primers for rhesus macaque *MLH1* gene sequencing is listed in Table S5. We used Sanger sequencing, and the SNP Detector 3.0 program (53) was used to identify

SNPs, insertions, and deletions in the *MLH1* gene region. The mutations on the *MLH1* gene region were annotated based on the Ensembl database (www.ensembl.org/) with two rhesus transcripts (ENSMMUT00000031714 with 15 exons and ENSMMUT00000031713 with 10 exons). The mutations on the unmapped rhesus scaffold were not annotated.

Pedigree Analysis. The pedigree analysis was performed with archival records of mating and births in the colony and diseased animal records. The data were analyzed using Cyrillic v.3 software (AP Benson, Ltd.).

More information about the *MLH1* promoter activity assay is provided in *SI Appendix*.

- Giddens WE, Jr, Dillingham LA (1971) Primary tumors of the lung in nonhuman primates. *Vet Pathol* 8:467–478.
- Nicholls J, Schwartz LW (1980) A spontaneous bronchiolo-alveolar neoplasm in a nonhuman primate. *Vet Pathol* 17:630–634.
- Lowenstine LJ (1986) Neoplasms and proliferative disorders in nonhuman primates. *Primates: The Road to Self-Sustaining Populations*, ed Benirschke K (Springer, New York), pp 781–814.
- Uno H, et al. (1998) Colon cancer in aged captive rhesus monkeys (*Macaca mulatta*). *Am J Primatol* 44:19–27.
- Simmons HA, Mattison JA (2011) The incidence of spontaneous neoplasia in two populations of captive rhesus macaques (*Macaca mulatta*). *Antioxid Redox Signal* 14: 221–227.
- Brack M (1998) Gastrointestinal tumors observed in nonhuman primates at the German primate center. *J Med Primatol* 27:319–324.
- Johnson EH, Morgenstern SE, Perham JM, Barthold SW (1996) Colonic adenocarcinoma in a rhesus macaque (*Macaca mulatta*). *J Med Primatol* 25:435–438.
- DePaoli A, McClure HM (1982) Gastrointestinal neoplasms in nonhuman primates: A review and report of eleven new cases. *Vet Pathol Suppl* 7:104–125.
- Kerrick GP, Brownstein DG (2000) Metastatic large intestinal adenocarcinoma in two rhesus macaques (*Macaca mulatta*). *Contemp Top Lab Anim Sci* 39:40–42.
- Lembo TM, Tinkey PT, Cromeens DM, Gray KN, Price RE (1997) Stenosing colonic adenocarcinoma in a female rhesus monkey. *J Med Primatol* 26:229–232.
- O'Sullivan MG, Carlson CS (2001) Colonic adenocarcinoma in rhesus macaques. *J Comp Pathol* 124:212–215.
- Valverde CR, Tarara RP, Griffey SM, Roberts JA (2000) Spontaneous intestinal adenocarcinoma in geriatric macaques (*Macaca sp.*). *Comp Med* 50:540–544.
- Ludvico L, et al. (2001) Demography and pedigree structure of an SPF colony of rhesus monkeys (*Macaca mulatta*). *Am J Primatol* 53:155–165.
- Nishii R, et al. (2012) Pharmacokinetics, metabolism, biodistribution, radiation dosimetry, and toxicology of (18)F-fluoroacetate ((18)F-FACE) in non-human primates. *Mol Imaging Biol* 14:213–224.
- Tian M, et al. (2011) Whole-body biodistribution kinetics, metabolism, and radiation dosimetry estimates of 18F-PEG6-IPQA in nonhuman primates. *J Nucl Med* 52: 934–941.
- Lynch HT, Shaw MW, Magnuson CW, Larsen AL, Krush AJ (1966) Hereditary factors in cancer. Study of two large midwestern kindreds. *Arch Intern Med* 117:206–212.
- Lynch HT, et al. (2009) Review of the Lynch syndrome: History, molecular genetics, screening, differential diagnosis, and medicolegal ramifications. *Clin Genet* 76:1–18.
- Gala M, Chung DC (2011) Hereditary colon cancer syndromes. *Semin Oncol* 38: 490–499.
- Samowitz WS, et al. (2001) The colon cancer burden of genetically defined hereditary nonpolyposis colon cancer. *Gastroenterology* 121:830–838.
- Aaltonen LA, et al. (1998) Incidence of hereditary nonpolyposis colorectal cancer and the feasibility of molecular screening for the disease. *N Engl J Med* 338:1481–1487.
- Vasen HF, et al. (2007) Guidelines for the clinical management of Lynch syndrome (hereditary non-polyposis cancer). *J Med Genet* 44:353–362.
- Vasen HF, et al. (2004) Identification of HNPCC by molecular analysis of colorectal and endometrial tumors. *Dis Markers* 20:207–213.
- Vasen HF, Mecklin JP, Khan PM, Lynch HT (1991) The International Collaborative Group on hereditary non-polyposis colorectal cancer (ICG-HNPCC). *Dis Colon Rectum* 34:424–425.
- Umar A, et al. (2004) Revised Bethesda guidelines for hereditary nonpolyposis colorectal cancer (Lynch syndrome) and microsatellite instability. *J Natl Cancer Inst* 96: 261–268.
- Bronner CE, et al. (1994) Mutation in the DNA mismatch repair gene homologue hMLH1 is associated with hereditary non-polyposis colon cancer. *Nature* 368:258–261.
- Fishel R, et al. (1993) The human mutator gene homolog MSH2 and its association with hereditary nonpolyposis colon cancer. *Cell* 75:1027–1038.
- Leach FS, et al. (1993) Mutations of a mutS homolog in hereditary nonpolyposis colorectal cancer. *Cell* 75:1215–1225.
- Papadopoulos N, et al. (1994) Mutation of a mutL homolog in hereditary colon cancer. *Science* 263:1625–1629.
- Nicolaides NC, et al. (1994) Mutations of two PMS homologues in hereditary non-polyposis colon cancer. *Nature* 371:75–80.
- Peltomäki P, Vasen H (2004) Mutations associated with HNPCC predisposition—Update of ICG-HNPCC/INSIGHT mutation database. *Dis Markers* 20:269–276.
- Lindblom A, Tannergård P, Werelius B, Nordenskjöld M (1993) Genetic mapping of a second locus predisposing to hereditary non-polyposis colon cancer. *Nat Genet* 5: 279–282.
- Boland CR, et al. (1998) Genetic instability and chromosomal aberrations in colorectal cancer: A review of the current models. *Cancer Detect Prev* 22:377–382.
- Boland CR, et al. (1998) A National Cancer Institute workshop on microsatellite instability for cancer detection and familial predisposition: Development of international criteria for the determination of microsatellite instability in colorectal cancer. *Cancer Res* 58:5248–5257.
- Haydon AM, Jass JR (2002) Emerging pathways in colorectal-cancer development. *Lancet Oncol* 3:83–88.
- Vasen HF (2007) Review article: The Lynch syndrome (hereditary nonpolyposis colorectal cancer). *Aliment Pharmacol Ther* 26:113–126.
- Kurzawski G, Suchy J, Debnik T, Kladny J, Lubiński J (2004) Importance of microsatellite instability (MSI) in colorectal cancer: MSI as a diagnostic tool. *Ann Oncol* 15: iv283–iv284.
- Gibbs RA, et al.; Rhesus Macaque Genome Sequencing and Analysis Consortium (2007) Evolutionary and biomedical insights from the rhesus macaque genome. *Science* 316:222–234.
- Brieger A, et al. (2011) Malignant fibrous histiocytoma is a rare Lynch syndrome-associated tumor in two German families. *Fam Cancer* 10:591–595.
- Simpkins SB, et al. (1999) MLH1 promoter methylation and gene silencing is the primary cause of microsatellite instability in sporadic endometrial cancers. *Hum Mol Genet* 8:661–666.
- Case AS, et al. (2008) Clustering of Lynch syndrome malignancies with no evidence for a role of DNA mismatch repair. *Gynecol Oncol* 108:438–444.
- Morak M, et al. (2008) Further evidence for heritability of an epimutation in one of 12 cases with MLH1 promoter methylation in blood cells clinically displaying HNPCC. *Eur J Hum Genet* 16:804–811.
- Zhong X, et al. (2007) A single nucleotide substitution (-107C->G) in the hMLH1 promoter found in colorectal cancer population reduces transcriptional activity. *Biochem Genet* 45:671–681.
- Green RC, et al. (2003) Germline hMLH1 promoter mutation in a Newfoundland HNPCC kindred. *Clin Genet* 64:220–227.
- Raptis S, et al. (2007) MLH1 -93G>A promoter polymorphism and the risk of microsatellite-unstable colorectal cancer. *J Natl Cancer Inst* 99:463–474.
- Gazzoli I, Loda M, Garber J, Syngal S, Kolodner RD (2002) A hereditary nonpolyposis colorectal carcinoma case associated with hypermethylation of the MLH1 gene in normal tissue and loss of heterozygosity of the unmethylated allele in the resulting microsatellite instability-high tumor. *Cancer Res* 62:3925–3928.
- Esteller M, Levine R, Baylin SB, Ellenson LH, Herman JG (1998) MLH1 promoter hypermethylation is associated with the microsatellite instability phenotype in sporadic endometrial carcinomas. *Oncogene* 17:2413–2417.
- Herman JG, et al. (1998) Incidence and functional consequences of hMLH1 promoter hypermethylation in colorectal carcinoma. *Proc Natl Acad Sci USA* 95:6870–6875.
- Zhou HH, et al. (2008) MLH1 promoter germline-methylation in selected probands of Chinese hereditary non-polyposis colorectal cancer families. *World J Gastroenterol* 14: 7329–7334.
- Germano G, et al. (2017) Inactivation of DNA repair triggers neoantigen generation and impairs tumour growth. *Nature* 552:116–120.
- Powell SM, ed (2001) *Colorectal Cancer: Methods and Protocols* (Humana Press, Totowa, NJ).
- Raveendran M, et al. (2006) Designing new microsatellite markers for linkage and population genetic analyses in rhesus macaques and other nonhuman primates. *Genomics* 88:706–710.
- Berg KD, et al. (2000) Detection of microsatellite instability by fluorescence multiplex polymerase chain reaction. *J Mol Diagn* 2:20–28.
- Zhang J, et al. (2005) SNPdetector: A software tool for sensitive and accurate SNP detection. *PLoS Comput Biol* 1:e53.